Anatomical and Scanning Electron Microscopic Characteristics of the Tongue in the Pampas Deer (Cervidae: *Ozotoceros bezoarticus*, Linnaeus 1758)

SERKAN ERDOĞAN[1]* AND WILLIAM PÉREZ[2]
[1]*Department of Anatomy, Faculty of Veterinary Medicine, Dicle University, 21280 Diyarbakir, Turkey*
[2]*Department of Anatomy, Faculty of Veterinary Medicine, University of the Republic, 11600 Montevideo, Uruguay*

KEY WORDS anatomy; scanning electron microscopy; tongue; deer

ABSTRACT This study represents the first definitive anatomical description of the tongue and lingual papillae of the pampas deer and compares the different information on the morphology of the other ruminant species available in the literature. In this study, the tongues of four adult and one fetal deer were used. The tongue was elongated with an oval or rounded apex. The filiform papillae on the lingual apex were smaller than the ones on the dorsal and lateral surfaces of the lingual body. Two very thin secondary papillary projections were found to emerge from the bilateral sides of some filiform papillae. Spherical fungiform papillae were randomly distributed among filiform papillae on dorsal surface of the lingual body and ventral surface of the apex. More developed conical papillae were observed in the caudal half of the lingual torus, whereas the rostral half of the torus had smaller conical papillae. Each conical papilla included shallow longitudinal groove on its anterior surface and some conical papillae on the lingual torus had bifid sharp apices. On the caudal portion of the torus, we also observed a few fungiform papillae, which were larger than those located on the lingual body. There were no lenticular papillae on the lingual torus, and five to nine round or oval circumvallate papillae were situated on each caudolateral side of the lingual torus. Morphological features of the tongue in the pampas deer were more similar to wild ruminant species than they were to domestic species. *Microsc. Res. Tech. 00:000–000, 2013*.

INTRODUCTION

The tongue plays a principal role in feeding function, together with other organs within and near the oral cavity. It has a characteristic form and specialized structures in tetrapods, especially mammals (Iwasaki, 2002). An important aspect of morphological studies of the tongue in mammals is the structure and distribution of lingual papillae on its dorsal surface. The results of macroscopic and microscopic observations showed that these features exhibit great variability in relation to the animal's lifestyle, diet, and adaptation to various environmental conditions and taxonomical features. From a comparative point of view, this variability is significant between high systematic units, such as orders or families, although there are also frequent interspecies differences (Erdogan and Alan 2012; Erdoğan et al., 2012; Iwasaki, 2002; Jackowiak and Godynicki, 2004; Kobayashi et al., 2005).

The studies of the ruminant tongue include gross anatomical observations (Emura et al., 2011a,b; Kobayashi et al., 2005; Shao et al., 2010), scanning electron microscopic evaluations (Chamorro et al., 1986; de Paz Cabello et al., 1988; Emura et al., 2011a,b; Kumar et al., 1998; Kurtul and Atalgın, 2008; Tadjalli and Pazhoomand, 2004), and light microscopic assessments (Agungpriyono et al., 1995; Atoji et al., 1998; Kocak Harem et al., 2011; Kokubun et al., 2012; Zheng and Kobayashi 2006). These studies have revealed interspecific variations in general morphology, structure, and distribution of papillae on the dorsal lingual surface.

The pampas deer (*Ozotoceros bezoarticus)* was once a widespread species, originally distributed in the open grasslands (pampas) across eastern South America, from 5° to 41°S (Jackson and Langguth, 1987). However, habitat loss, unregulated hunting, competition with cattle, and transmission of cattle diseases have caused a drastic decrease in pampas deer populations (Jackson and Giullieti, 1988). Although there are small wild populations in Argentina, Brazil, and Uruguay (González, 1993), it is considered to be in extreme danger of extinction (González and Merino, 2008).

Pampas deer have been observed eating new green growth, shrubs, and herbs. Most of the plant life they consume grows in moist soils. The pampas deer eats less grass and more forbs (flowering broad leafed plants with soft stems) and browse (shoots, leaves, and twigs) (Villa et al., 2008). It is a peculiarity among the

*Correspondence to: Serkan Erdoğan; Department of Anatomy, Faculty of Veterinary Medicine, Dicle University, 21280 Diyarbakir, Turkey.
E-mail: serkanerdogan101@hotmail.com

Received 15 May 2013; accepted in revised form 30 June 2013

Contract grant sponsors: CIDEC (Facultad de Veterinaria, Uruguay), CSIC (Universidad de la República, Uruguay), and Intendencia Municipal de Maldonado.

DOI 10.1002/jemt.22263
Published online 00 Month 2013 in Wiley Online Library (wileyonlinelibrary.com).

cervids; most of which; are considered to be either browsers (i.e., the natural diet consists mainly of dicotyledonous forage, like tree foliage, forbs, herbs, or wild fruits) or intermediate feeders (i.e., consuming monocotyledonous forage-grasses-to a certain degree, mostly dependent on seasonal variation in forage availability) (Hofmann, 1985).

The majority of the anatomical studies related to pampas deer have focused on the reproductive system (Pérez et al., 2013a,b) and lower digestive system (Pérez et al., 2008; Pérez and Ungerfeld, 2012). Our literature review indicates that no morphological evaluation exists, on the detailed morphological aspects of the tongue in the pampas deer. In this study, our aim is to study comparatively the gross anatomical features of the tongue and scanning electron microscopic morphologies and the topographical distribution of the lingual papillae that reside on all of the lingual surfaces in the pampas deer. Additionally, we will compare our findings with reports on other ruminant species.

MATERIALS AND METHODS

The tongues of four adult pampas deer (*Ozotoceros bezoarticus)* and one fetus were used in this study. The average weight of the mature animals was 14.22 ± 0.92 kg. Precise fetal age was not determined and crown-rump length of the fetus was 136 mm. Animals were obtained from a captive breeding station, "Estación de Cría de Fauna Autóctona", Pan de Azúcar, Maldonado, Uruguay (ECFA; 34°3'S, 55°1'W; altitude: approximately 200 m). Four dead adult animals and one fetus were evaluated for this research. There were no abnormalities in oral cavity, and the cause of dead was not determined. The animals were dissected and their tongues, after removal, were washed in 0.1 M chilled phosphate buffer (pH-7.4), fixed in 2.5% glutaraldehyde for 6 h, and again washed twice in 0.1 M phosphate buffer (pH-7.4). Secondary fixation was carried out in 1% osmium tetroxide for 1 h and specimens dehydrated by acetone. Then, they were critical point dried and coated with gold palladium. The specimens were observed and photographed under a scanning electron microscope (Jeol JSM-5900LV, Jeol Ltd., Tokyo, Japan). The extracted tissues were examined under a stereomicroscope (Nikon SMZ800, Tokyo, Japan) to determine their general anatomical characteristics before examination by scanning electron microscopy. Terms are used in agreement with the Nomina Anatomica Veterinaria (2012). Data were presented as median ± standard error.

RESULTS

Gross Anatomy

The tongue is composed of three parts: apex, body, and root (Fig. 1a). In the pampas deer, the tongue was fairly elongated and terminated in an oval or rounded apex (Fig. 1a). The widths of the tongue were consistent along its length (22.79 ± 2.58, 25.14 ± 2.15, 29.24 ± 2.10, and 26.38 ± 1.48 mm in the apex, body, torus, and radix, respectively). The total length of the tongue, from its root to the apex, was 112.34 ± 4.93 mm, and the greatest thickness of the tongue was in the torus (15.98 ± 0.46 mm). Other thicknesses were 6.04 ± 0.66, 12.00 ± 0.52, and 12.88 ± 0.86 mm in the apex, body, and radix, respectively. The median sulcus in 31.03 ± 2.30 mm, which extended from the apex to rostral one-third part of the tongue, was evident on the dorsal lingual surface (Fig. 1a). The marked trench (fossa linguae) between the rostral two-thirds and caudal one-third part of the body and the lingual torus (*torus linguae*) just behind it were observed. The caudal one-third of the body was formed by a fairly bulky lingual torus (Fig. 1a). The ventral surface of the tongue was connected to the floor of oral cavity through a broad frenulum (*frenulum linguae*) at the level of the border between the rostral and central one-third of the tongue (Fig. 2). The anatomical measurements of the tongue were also shown in Table 1.

Stereomicroscopy

Macroscopically, two types of mechanical (filiform and conical) and two types of gustatory (fungiform and circumvallate) papillae were observed on the dorsal surface of the tongue. Filiform papillae, which were the most numerous type of papillae, covered the dorsal and lateral surfaces of the rostral two-thirds of the tongue (Figs. 1b and 1c). In the caudal one-third of the tongue, filiform papillae were located on the lateral surfaces of the tongue only. Other types of mechanical papillae were conical papillae located on the dorsal surface of the lingual torus (Figs. 1d and 1e). A few rounded fungiform papillae were interspersed among the huge conical papillae, especially on the caudal half of the torus (Fig. 1e).

Fungiform papillae were round and distributed randomly, particularly on the rostral one-third of the dorsal surface of the tongue and lingual torus (Figs. 1b, 1c and 1e). Densities of the fungiform papillae on the apex gradually decreased in number toward the medial region of the body. The fungiform papillae of the lingual torus were bigger and more spherical than those located on the apex and body, and were distributed among the many conical papillae of the lingual torus (Fig.1e). Interestingly, filiform and fungiform papillae were also restricted to the ventral surface of the apex and the lateral edges of the ventral surface of rostral half of the body (Fig. 2). The median region of the ventral surface of the tongue was covered with a smooth mucosa without any mechanical or gustatory papillae. There were no lenticular papillae on the entire dorsal surface of the body (Fig. 1).

The circumvallate papillae were located on the lateral edges of the caudal half of the lingual torus. In both caudolateral edges, an average of five to nine circumvallate papillae formed a longitudinal ridge (Figs. 1f and 1g). Circumvallate papillae varied in diameter and approached the size of fungiform papillae. The bodies of the circumvallate papillae were surrounded by a continuous trench (Fig. 1g). In contrast to the apex, lingual body, and lingual torus, no mechanical or gustatory papillae were present on the radix of the tongue.

Scanning Electron Microscopy

The dorsal surface of the tongue was covered with densely distributed filiform papillae; however, differences were observed among the sizes of papillae in the different regions of the tongue. The filiform papillae on the lingual apex were smaller and thinner

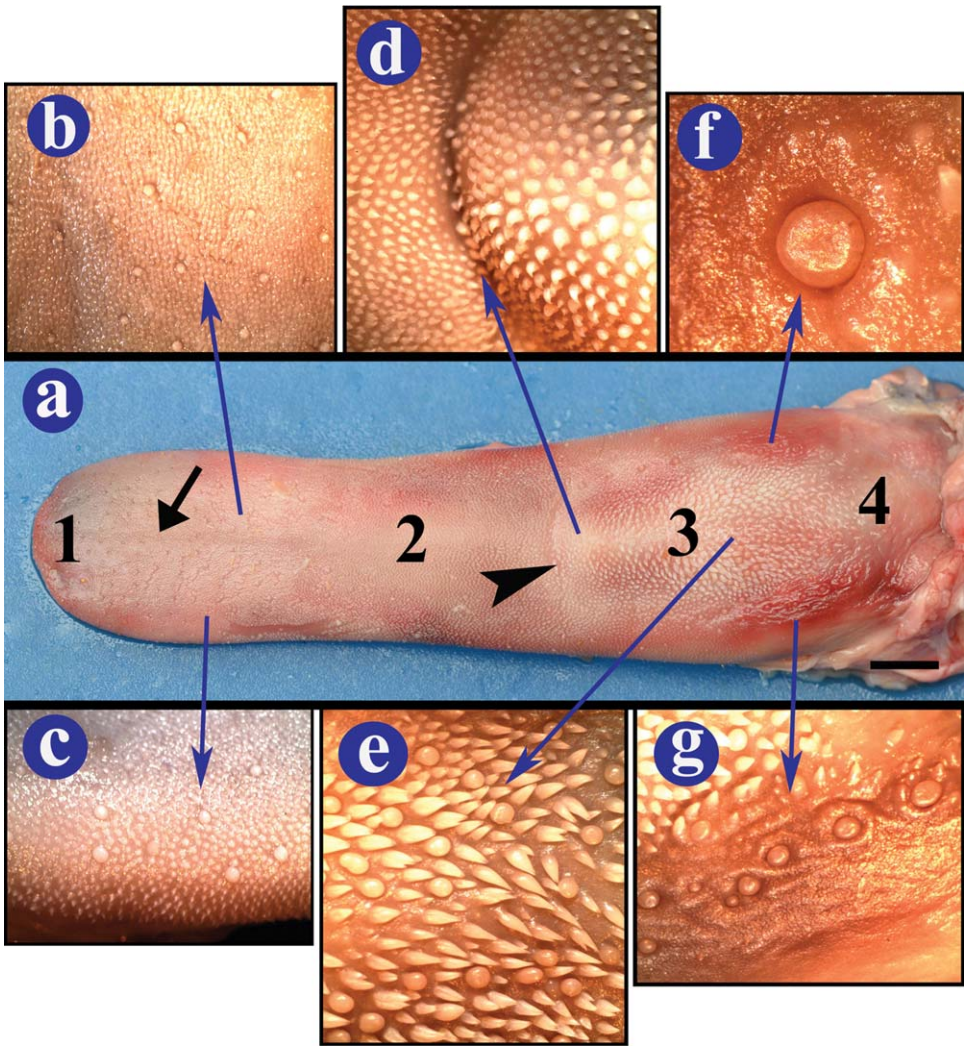

Fig. 1. Anatomical view of the dorsal surface of the tongue **(a)**. 1: apex, 2: body, 3: torus, 4: radix, arrow: Median sulcus, arrowhead: lingual fossa, **(b–c)** filiform and fungiform papillae of the lingual body, **(d–e)** conical and fungiform papillae of the lingual torus, **(f–g)** circumvallate papillae. Bar: 1 cm. [Color figure can be viewed in the online issue, which is available at wileyonlinelibrary.com.]

(Table 2) than the ones on the dorsal and lateral surfaces of the lingual body (Table 2, Fig. 3). Spherical or rounded fungiform papillae were randomly distributed and embedded among the short filiform papillae, which angled caudally on the dorsal surface of the apex (Fig. 3). As for the ventral surface of the apex, the shapes and sizes of fungiform papillae were varied (Table 2), with some whose edges touched each other, forming small clusters (Fig. 4). Most of the fungiform papillae in the ventral surface of the apex were round. The remainder of the papillae were elliptical or irregularly shaped due to being in close contact with one another (Fig. 4). The convex fungiform papillae were covered by squamous epithelial cells, and several taste pores were observed on the convex dorsal surface at higher magnification. Taste pores were especially numerous on the dorsal surface of the fungiform papillae on the ventral surface of apex of the tongue (Fig. 4).

We also noted that smaller filiform papillae (Table 2) on the ventral apex of the tongue were more irregular than those on the dorsal surface of the apex. Moreover, some thin filiform papillae on the ventral surface of apex were perpendicular to tongue's surface or were angled cranially (Figs. 3 and 4).

The filiform papillae of the dorsal surface of the lingual body were of typical triangular shape. Radices of the filiform papillae were bulky and at the surfaces of the papillae there were numerous scale-like structures resulting from desquamated keratinized cells (Fig. 5). The filiform papillae on the surface of the lingual body, compared to those localized on the apex and ventral surface of the tongue, were neither not irregular in shape nor angled in different directions, but were angled typically in the caudal direction (Figs. 5a and 5b). On the rostral half of the lingual body, fungiform papillae were especially numerous and randomly distributed among densely distributed filiform papillae

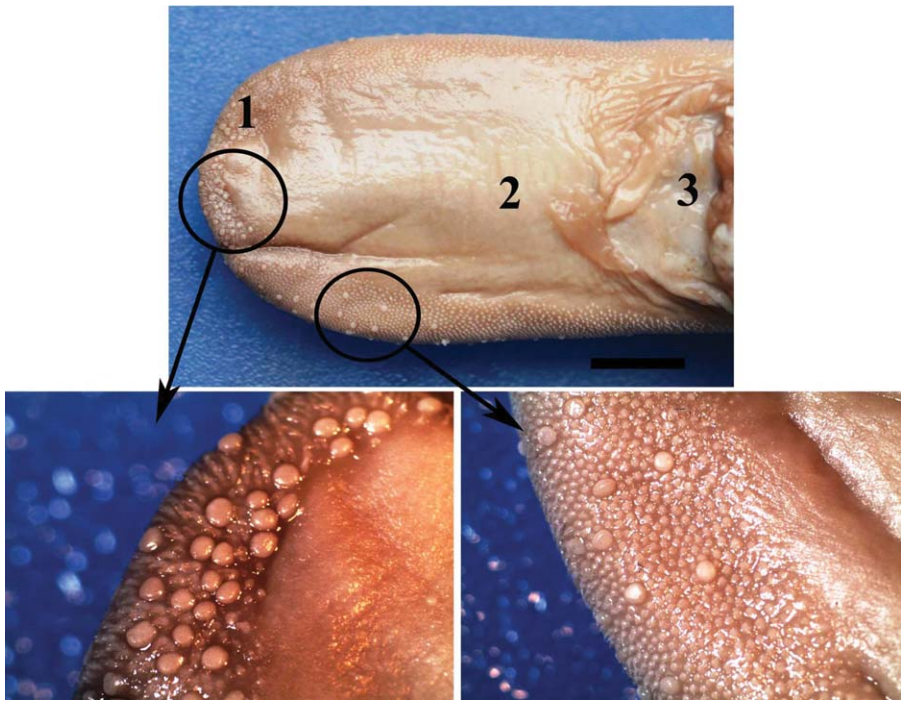

Fig. 2. Filiform and fungiform papillae (in circles) on the ventral surface of the tongue. 1: apex, 2: body, 3: frenulum. Bar: 1 cm. [Color figure can be viewed in the online issue, which is available at wileyonlinelibrary.com.]

TABLE 1. The macroanatomic measurements of the tongue (mm) (mean ± SE)

Total length of the tongue	Length of the median sulcus	Widths of the tongue				Thicknesses of the tongue			
		Apex	Body	Torus	Radix	Apex	Body	Torus	Radix
112.34 ± 4.93	31.03 ± 2.30	22.79 ± 2.58	25.14 ± 2.15	29.24 ± 2.10	26.38 ± 1.48	6.04 ± 0.66	12.00 ± 0.52	15.98 ± 0.46	12.88 ± 0.86

TABLE 2. The measurements of the lingual papillae according to localization (μm) (mean ± SE)

Filiform papillae			Fungiform papillae			Conical papillae		Circumvallate papillae
Dorsal surface of the lingual apex	Ventral surface of the lingual apex	Lingual body	Ventral surface of the lingual apex	Lingual body	Caudal half of the lingual torus	Rostral half of the lingual torus	Caudal half of the lingual torus	Caudal half of the lingual torus
358.00 ± 8.68	243.00 ± 16.07	433.75 ± 9.52	413.42 ± 16.18	412.00 ± 6.00	871.00 ± 0.42	628.00 ± 33.70	1230.00 ± 50.00	862.50 ± 51.50

(Figs. 5a and 5c). In addition to these filiform papillae on the rostral portion of the body that tilted caudally (Fig. 5b), we observed filiform papillae oriented perpendicular to the surface of the tongue on the caudal portion of the body and just in front of lingual torus. These large filiform papillae on the caudal portion of the body possessed pointed tips that tilted caudally (Fig. 5d). Two secondary papillary projections were significantly thin, and emerged from bilateral sides of some filiform papillae on the rostral half of the lingual body (Fig. 5d).

More developed and higher conical papillae (Table 2), the sharp apices of which were pointed towards the lingual radix, were observed in the caudal half of the lingual torus (Fig. 6b), whereas the rostral half of the dorsal surface of the torus had smaller and shorter conical papillae (Table 2 and Fig. 6a). The basal portions of the conical papillae were fairly bulky and each conical papilla included a shallow longitudinal groove on its anterior surface (Figs. 6b and 6d). The papillary surfaces of the conical papillae were smooth and there were no secondary projections (Fig. 6d); however, some conical papillae located centrally on the lingual torus had bifid sharp apices (Fig. 6e). In addition to the presence of conical papillae on the caudal portion of torus, we observed a few fungiform papillae among large conical papillae (Figs. 6b and 6c). Round fungiform papillae were larger than those located on the lingual body (Table 2 and Fig. 6c). Although conical papillae were located on both the dorsal and lateral surfaces of the lingual torus (Figs. 6a and 6b), round fungiform papillae were located on the dorsal surface only of the caudal half of the torus (Fig. 6b).

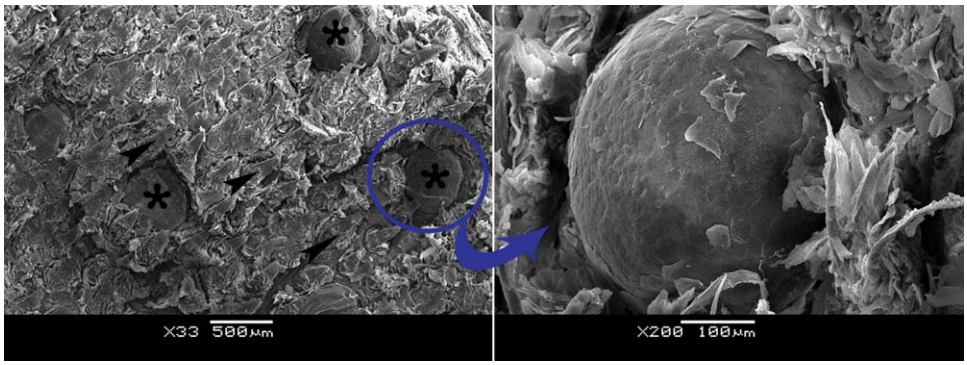

Fig. 3. Dorsal surface of the lingual apex. Arrowheads: filiform papillae, *: fungiform papillae. [Color figure can be viewed in the online issue, which is available at wileyonlinelibrary.com.]

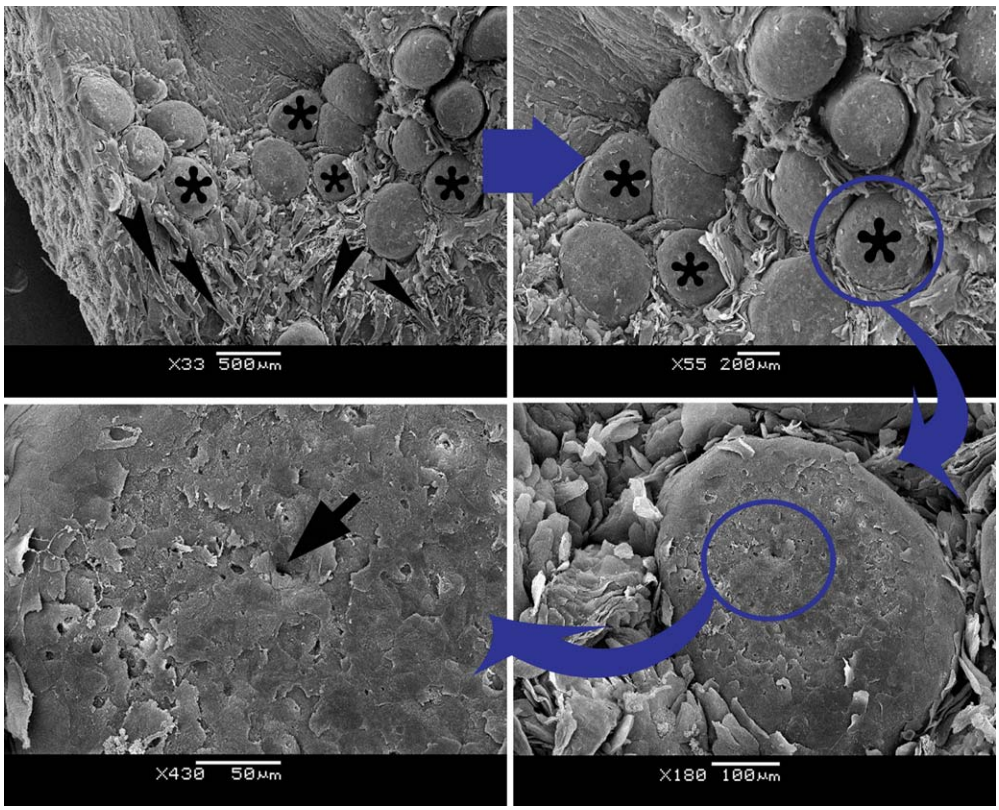

Fig. 4. Ventral surface of the lingual apex. Arrowheads: filiform papillae, Arrow: taste pore on the dorsal surface of fungiform papillae (*). [Color figure can be viewed in the online issue, which is available at wileyonlinelibrary.com.]

Round or oval circumvallate papillae were located parallel to the median line of the tongue on each caudolateral side of the lingual torus. Each circumvallate papilla had a flat surface and the bodies of vallate papillae were surrounded by a prominent and continuous gustatory groove (Table 2, Fig. 7). Small conical papillae of the lingual torus were located near the circumvallate papillae (Fig. 7).

In addition to the observation of mature tongues, we also observed a fetal tongue. In the fetal tongue, we could not detect filiform or circumvallate papillae on its dorsal surface, but conical and fungiform papillae were developing on the lingual torus and were appeared as papillary swellings during the developmental process (Fig. 8).

DISCUSSION

Different morphological structures of the tongues of vertebrates are specialized to fulfil different functions, such as swallowing, water uptake, capturing and manipulating the food, grooming, vocal modulation, and suckling (Kilinc et al., 2010; Mançanares et al.,



Fig. 5. Dorsal surface of the lingual body. **(a–c)** Filiform (arrowheads) and fungiform (*) papillae of the rostral half of the body, arrows: taste pores, **(d)** filiform papillae (arrowheads) of the caudal half of the body, arrows: secondary projections. [Color figure can be viewed in the online issue, which is available at wileyonlinelibrary.com.]

2012; Pastor et al., 2011). Furthermore, the mammalian tongue exhibits different morphological adaptations in different species. The distribution of the different papillae on the various surfaces of the tongue is characteristic of a genus and may even be distinctive among different species. One of the elements that contribute most to the morphological, distribution, and type of papillae is diet (Pastor et al., 2011). Morphological differences and variations appearing in the tongue are directly associated with dietary specializations and food type, as well as adaptations to various environmental conditions (Iwasaki, 2002).

In this study, we determined the presence of fungiform and filiform papillae on the ventral surface of the apex of the tongue, in addition to its dorsal surface. Filiform papillae of the pampas deer were densely distributed over the entire dorsal surface of the tongue except for the radix and lingual torus, and these increased in size from the lingual apex to the lingual body. Similarly, a great number of filiform papillae are present particularly on the rostral half of the dorsal lingual surface in goats (Kumar et al., 1998; Kurtul and Atalgın, 2008), goitered gazelle (Kocak Harem et al., 2011), sitatunga (Emura et al., 2011b), and barking deer (Adnyane et al., 2011). However, in some ruminants, the filiform papillae consist of a larger main papilla with smaller secondary papillae (Agungpriyono et al., 1995; Emura et al., 2011a,b; Kocak Harem et al., 2011; Kurtul and Atalgın, 2008). Three to six secondary projections on the filiform papillae were reported in the Saanen goat (Kurtul and Atalgın, 2008), whereas two were reported in the Formosan serow (Atoji et al., 1998) and goitered gazelle (Kocak Harem et al., 2011), two to three in the lesser mouse deer (Agungpriyono et al., 1995), six to eight in goats (Kumar et al., 1998), two to four in Bactrian camel (Erdunchaolu et al., 2001), and one projection was reported in a one humped camel (Qayyum et al., 1988). Similar to the Formosan serow (Atoji et al., 1998) and goitered gazelle (Kocak Harem et al., 2011), there were two secondary papillae that originated from the basal portion of the main filiform papilla on the rostral half of the tongue in the pampas deer. These secondary papillae were detected on only the rostral half of the tongue in the lesser mouse deer (Agungpriyono et al., 1995) and the lingual apex in the goitered gazelle (Kocak Harem et al., 2011). The tips of the filiform papillae of the lingual apex displayed some sharp-pointed thread-like projections (Kocak Harem et al., 2011; Kumar et al., 1998), and those of the lingual body have two sharply-pointed projections in goitered gazelle (Kocak Harem et al., 2011). In our study, the tips of the filiform papillae, which were distributed on the dorsal lingual surface, possessed only one sharp-pointed tip, and we discovered numerous scale-like structures as a result of desquamated keratinized cells on the surfaces of filiform papillae as reported in the cow (de Paz Cabello et al., 1988) and mazama species (Kokubun



Fig. 6. Dorsal surface of the lingual torus. **(a)** Conical papillae (arrowheads) on the rostral portion of the lingual torus, **(b–d)** Conical (arrowheads) and fungiform (*) papillae on the caudal portion of the lingual torus, arrows: Shallow groove on anterior surface of the conical papilla, **(e)** conical papilla with bifid projections (arrows). [Color figure can be viewed in the online issue, which is available at wileyonlinelibrary.com.]

et al., 2012). Differences in the types and distribution of filiform papillae among animals appear to be related to age, food, and feeding, and mastication pattern (Erdunchaolu et al., 2001).

The fungiform papillae were large dome-shaped eminences on the lingual mucosa with almost spherical bodies with a round bases and a convex upper surfaces in the pampas deer. This rounded or convex morphological shape of fungiform papillae are reported in wild (Atoji et al., 1998; Emura et al., 2011a; Kocak Harem et al., 2011; Kokubun et al., 2012) and domestic ruminants (Emura et al., 2000; Kumar et al., 1998; Kurtul and Atalgın, 2008). In this study, we found that there were numerous fungiform papillae especially on the ventral surface and tip of the apex of the tongue. Likewise, fungiform papillae were also densely distributed on the ventral surface and tip of the tongue in Formosan serow (Atoji et al., 1998), Japanese serow (Funato et al., 1985), roan antelope (Emura et al., 2011a), blackbuck (Emura et al., 1999), Barbary sheep (Emura et al., 2000), and lesser mouse deer (Agungpriyono et al., 1995), and the papillae were smaller than the fungiform papillae of the body. On the other hand, the fungiform papillae in the lesser mouse deer (Agungpriyono et al., 1995) were larger and distributed abundantly at the apex of the tongue. According to Agungpriyono et al. (1995), the apex of the tongue can therefore be considered a special organ, transmitting

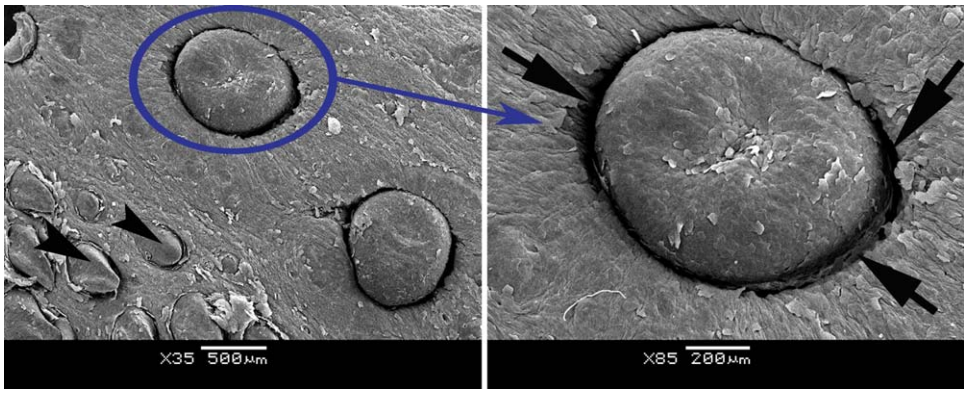

Fig. 7. Circumvallate papilla that is encircled by a continuous trench (arrows). Arrowheads: small conical papillae of the lingual torus. [Color figure can be viewed in the online issue, which is available at wileyonlinelibrary.com.]



Fig. 8. Developing conical (arrowheads) and fungiform (arrows) papillae on the dorsal surface of the fetal lingual body.

several kinds of sensory information. Different from other ruminants, a few truncated projections emerging from the lateral side of the surface of the fungiform papillae were detected in the one humped camel (Qayyum et al., 1988).

In the goitered gazelle (Kocak Harem et al., 2011), two types of fungiform papillae were distinguished according to their localization. The first type included small, round fungiform papillae that were distributed on the lingual apex and body. The second type of fungiform papillae was distributed along the lateral side of the torus. Similar to the gazelle (Kocak Harem et al., 2011), two types of fungiform papillae have been identified in the barking deer (Adnyane et al., 2011) and Formosan serow (Atoji et al., 1998). In the pampas deer, fungiform papillae were also located at the torus of the tongue and were larger than those located on the apex and body, and we also detected bigger fungiform papillae on the caudal part of the lingual torus only. In mazama species (Kokubun et al., 2012), fungiform papillae were found on the central region of the lingual torus. In general, morphostructure and topographical distribution of the fungiform papillae observed in this study were more similar to those reported in the gazelle (Kocak Harem et al., 2011), Formosan serow (Atoji et al., 1998), and mazama species (Kokubun et al., 2012). In some ruminants (Adnyane et al., 2011; Atoji et al., 1998; Kumar et al., 1998; Kurtul and Atalgın, 2008; Tadjalli and Pazhoomand, 2004; Zheng and Kobayashi 2006) and camels (Erdunchaolu et al., 2001; Qayyum et al., 1988), fungiform papillae had a deep papillary groove, which separated them from the filiform papillae. There were no deep papillary grooves surrounding the fungiform papillae of the pampas deer. The convex fungiform papillae with flat surfaces were covered by squamous epithelial cells, and several taste pores were observed on the convex surface of each papilla. Similar to the pampas deer, taste pores can be observed on the surface of the fungiform papillae in the one humped camel (Qayyum et al., 1988), barking deer (Adnyane et al., 2011), Formosan serow (Atoji et al., 1998), and Japanese serow (Funato et al., 1985). In the goitered gazelle (Kocak Harem et al., 2011) and the goat (Kumar et al., 1998), no taste buds or pores were recognizable on the dorsal surface of the fungiform papillae.

Despite the variety of items eaten, deer mostly feed on the soft, juicy parts of plants that are easily digestible, such as new leaves, buds, and flowers. The pampas

deer feeds mainly on grass, but also eats dicotiledonean herbs. Despite the fact that pampas deer are selector ruminants, ingesting mainly buds and new leaves (Rodrigues and Monteiro-Filho, 1999), their fungiform papillae were distributed on dorsal and ventral surfaces of the lingual apex, and the dorsal and lateral surfaces of the lingual body and torus. We propose that the rich distribution of the gustatory papillae on these surfaces of the tongue plays an important role in detecting and selecting nutrients.

In this study, there were about 10–18 circumvallate papillae on both caudolateral sides of the lingual torus, which were arranged in one line cranially and each encircled by a deep groove. The number of the circumvallate papillae that are located bilaterally along the caudolateral side of the lingual torus varies among ruminants. Twenty-six circumvallate papillae were described in the Saanen goat (Kurtul and Atalgın, 2008) and the goitered gazelle (Kocak Harem et al., 2011), 10–13 in barking deer (Adnyane et al., 2011), two to five in the lesser mouse deer (Agungpriyono et al., 1995), 23 in the Formosan serow (Atoji et al., 1998), 20 in the Japanese serow (Funato et al., 1985), 22–28 in the yak (Shao et al., 2010), 22–32 in cattle (Shao et al., 2010), and 9–12 in the one humped camel (Qayyum et al., 1988). Vallate papillae were arranged in two lines in the Saanen goat (Kurtul and Atalgın, 2008), Bactrian camel (Erdunchaolu et al., 2001), and *Mazama americana* (Kokubun et al., 2012). The prominent gustatory groove and the annular pad of the surrounding lingual mucosa were reported in the goitered gazelle (Kocak Harem et al., 2011), the goat (Kumar et al., 1998; Kurtul and Atalgın, 2008), the roan antelope (Emura et al., 2011a), lamb (Tadjalli and Pazhoomand, 2004), and cattle (Chamorro et al., 1986). In the pampas deer, the annular pad was detected around some circumvallate papillae. In the one humped camel (Qayyum et al., 1988), about two or three vallate papillae were surrounded by primary and secondary grooves, and unique wart-like papillae were found on the posterior one-third of the tongue in close proximity to the circumvallate papillae. Differing from this study and reports of other ruminants, several foliate papillae were observed on both caudolateral sides, ventral to the vallate papillae in the lesser mouse deer (Agungpriyono et al., 1995).

Conical papillae, described on the lingual torus, were elongated with a round base and sharp tip without any projections or secondary papillae in the pampas deer. Similarly in the goat (Kumar et al., 1998), barking deer (Adnyane et al., 2011), goitered gazelle (Kocak Harem et al., 2011), Formosan serow (Atoji et al., 1998), and cow (de Paz Cabello et al., 1988), conical papillae were found on the dorsal and lateral surfaces of the lingual torus. In the cow (de Paz Cabello et al., 1988) and the goat (Kumar et al., 1998), these papillae were cone-shaped and oriented at a caudal angle; they were associated with a distinct groove surrounding their base and separating them from the rest of the lingual surface. We could not see similar grooves in the base of the conical papillae in our study of the pampas deer. In addition to conical papillae on the lingual torus, numerous lenticular papillae were reported in domestic ruminants (de Paz Cabello et al., 1988; Kumar et al., 1998; Kurtul and Atalgın, 2008) and the goitered gazelle (Kocak Harem et al., 2011). In the Bactrian camel (Erdunchaolu et al., 2001), the sitatunga (Emura et al., 2011b) and the roan antelope (Emura et al., 2011a), lenticular papillae were reported only on the lingual torus. In the pampas deer, no lenticular papillae were found on the lingual torus as reported in barking deer (Adnyane et al., 2011) and Formosan serow (Atoji et al., 1998). In this study, it was determined that the lingual torus possesses only conical and large fungiform papillae, as in the goitered gazelle (Kocak Harem et al., 2011), mazama species (Kokubun et al., 2002), and the Reeves' muntjac deer (Zheng and Kobayashi, 2006).

In this detailed study, we determined the topography of four types of lingual papillae including filiform, fungiform, conical, and circumvallate papillae; established the presence of fungiform and filiform papillae on the ventral surface of the apex, in addition to the dorsal surface; and clarified the special organization of conical and fungiform papillae on the lingual torus in the pampas deer. Particularly, we noted the presence of conical papillae with bifid projections on the dorsal surface of the torus, and the occurrence of secondary projections of some filiform papillae. In this study, we also focused on the general anatomical features of tongue. In general, this study establishes similarities in the anatomy of the tongue of the pampas deer with wild deer species, such as the gazelle and mazama species, with special attention to the lingual papillae. In contrast, our findings indicate few similarities of lingual morphology of pampas deer with domestic ruminants.

ACKNOWLEDGEMENTS

The authors acknowledge Dr. R. Ungerfeld and the Intendencia Municipal de Maldonado, for the facilities to develop research with deer of the ECFA. The authors would like to thank Dr. Brooke Hopkins Dubansky for her valuable contributions to the language improvement.

REFERENCES

Adnyane IKM, Zuki AB, Noordin MM, Agungpriyono S. 2011. Morphological study of the lingual papillae in the barking deer, Muntiacus muntjak. Anat Histol Embyol 40:73–77.

Agungpriyono S, Yamada J, Kitamura N, Nisa C, Sigit K, Yamamoto Y. 1995. Morphology of the dorsal lingual papillae in the lesser mouse deer, Tragulus javanicus. J Anat 187:635–640.

Atoji Y, Yamamoto Y, Suzuki Y. 1998. Morphology of the tongue of a male Formosan serow *(Cupricornis crispus swinhoei)* Anat Histol Embryol 27:17–19.

Chamorro CA, de Paz P, Sandoval J, Fernandez JG. 1986. Comparative scanning electron-microscopic study of the lingual papillae in two species of domestic mammals (Equus caballus and Bos taurus) I. Gustatory Papillae. Acta Anat 125:83–87.

de Paz Cabello P, Chamorro CA, Sandoval J, Fernandez M. 1988. Comparative scanning electron-microscopic study of the lingual papillae in two species of domestic mammals (Equus caballus and Bos taurus). II. Mechanical papillae. Acta Anat 132:120–123.

Emura S, Tamada A, Hayakawa D, Chen H, Yano R, Shoumura S.1999. Morphology of the dorsal lingual papillae in the blackbuck, *Antilope cervicapra*. Okajimas Folia Anat Jpn 76:247–253.

Emura S, Tamada A, Hayakawa D, Chen H, Shoumura S. 2000. Morphology of the dorsal lingual papillae in the Barbary sheep, Ammotragus lervia. Okajimas Folia Anat Jpn 77:39–45.

Emura S, Okumura T, Chen H. 2011a. Morphology of the lingual papillae in the roan antelope. Okajimas Folia Anat Jpn 88(3):127–131.

Emura S, Okumura T, Chen H. 2011b. Morphology of the lingual papillae in the sitatunga. Okajimas Folia Anat Jpn 88(1):23–27.

Erdogan S, Alan A. 2012. Gross anatomical and scanning electron microscopic studies of the oropharyngeal cavity in the European magpie (Pica pica) and the common raven (Corvus corax). Microsc Res and Tech 75:379–387.

Erdoğan S, Pérez W, Alan A. 2012. Anatomical and scanning electron microscopic investigations of the tongue and laryngeal entrance in the long-legged buzzard (*Buteo rufinus*, Cretzschmar, 1829) Microsc Res Tech 75:1245–1252.

Erdunchaolu E, Takehana K, Yamamoto E, Kobayashi A, Cao G, Aiyin B, Ueda H, Tangkawattana P. 2001. Characteristics of dorsal lingual papillae of the Bactrian camel (Camelus bactrianus). Anat Histol Embryol 30:147–151.

Funato H, Atoji Y, Suzuki Y, Sugimura M. 1985. Morphological studies on the tongue of wild Japanese serows, Capricornis crispus. Res Bull Fac Agr Gifu Univ 50:205–219.

González S. 1993. Situación poblacional del venado de campo en el Uruguay. In: CBSG/IUCN, editor. Pampas deer population and habitat viability assessment, Section 6. Apple Valley, MN: Workshop Briefing Book, pp. 1–9.

González S, Merino ML. 2008. Ozotoceros bezoarticus. In: IUCN 2013. IUCN red list of threatened species. Available at: <www.iucnredlist.org>. Downloaded on May 12, 2013.

Hofmann RR. 1985. Digestive physiology of the deer-their morphophysiological specialization and adaptation. R Soc NZ Bull 22: 393–407.

Iwasaki S. 2002. Evolution of the structure and function of the vertebrate tongue. J Anat 201:1–13.

Jackowiak H, Godynicki S. 2004. The scanning electron microscopic study of lingual papillae in the silver fox (Vulpes vulpes fulva, Desmarest, 1820). Ann Anat 186:179–183.

Jackson J, Giullieti J. 1988. The food of pampas deer Ozotoceros bezoarticus celer in relation to its conservation in relict natural grassland in Argentina. Biol Conserv 45:1–10.

Jackson J, Langguth A. 1987. Ecology and status of pampas deer (Ozotoceros bezoarticus) in the Argentinean pampas and Uruguay. In: Wemmer C, editor. Biology and management of the Cervidae. Washington, D.C: Smithsonian Institution Press, pp. 402–409.

Kilinc M, Erdogan S, Ketani S, Ketani MA. 2010. Morphological study by scanning electron microscopy of the lingual papillae in the Middle East blind mole rat (Spalax ehrenbergi, Nehring, 1898). Anat Histol Embryol 39(6):509–515.

Kobayashi K, Jackowiak H, Frackowiak H, Yoshimura K, Kumakura M. 2005. Comparative morphological study on the tongue and lingual papillae of horses (Perissodactyla) and selected ruminantia (Artiodactyla). Ital J Anat Embryol 110:55–63.

Kocak Harem M, Harem IS, Karadag Sari E, Aydin MF. 2011. Light and scanning electron microscopic study of the dorsal lingual papillae of the goitered gazelle (Gazelle subgutturosa). J Anim Vet Adv 10 (15):1906–1913.

Kokubun HS, Zanatta Esper GV, Rezende Franciolli AL, de Oliveira e Silva FM, Rici REG, Miglino MA. 2012. Estudo histológico e comparativo das papilas linguais dos cervídeos Mazama Americana e Mazama gouzoubira por microscopia de luz e eletrônica de varredura. Pesq Vet Bras 32(10):1061–1066.

Kumar P, Kumar S, Singh Y. 1998. Tongue papillae in goat: A scanning electron-microscopic study. Anat Histol Embryol 27:355–357.

Kurtul I, Atalgın HS. 2008. Scanning electron microscopic study on the structure of the lingual papillae of the Saanen goat. Small Rumin Res 80:52–56.

Mançanares CAF, Santos AC, Piemonte MV, Vasconcelos BG, Carvalho AF, Miglino MA, Ambrósio CE, Assis Neto AC. 2012. Macroscopic and microscopic analysis of the tongue of the common opossum (Didelphis marsupialis). Microsc Res Tech 75 (10):1329–1333.

Nomina Anatomica Veterinaria. 2012. International Committee on Veterinary Gross Anatomical Nomenclature (I.C.V.G.A.N.), Revised 5th ed. Available at: www.wava-amav.org.

Pastor JF, Barbosa M, De Paz FJ, García M, Ferrero E. 2011. Functional and comparative study of lingual papillae in four species of bear (Ursidae) by scanning electron microscopy. Microsc Res Tech 74:910–919.

Pérez W, Ungerfeld R. 2012. Gross anatomy of the stomach of the pampas deer, *Ozotoceros bezoarticus* (Artiodactyla: Cervidae) Zoologia 29: 337–342.

Pérez W, Clauss M, Ungerfeld R. 2008. Observations on the macroscopic anatomy of the intestinal tract and its mesenteric folds in the pampas deer (*Ozotoceros bezoarticus*, Linnaeus 1758) Anat Histol Embryol 37:317–321.

Pérez W, Vazquez N, Ungerfeld R. 2013a. Gross anatomy of the male genital organs of the pampas deer (Ozotoceros bezoarticus, Linnaeus 1758). Anat Sci Int 88(3):123–129.

Pérez W, Vazquez N, Ungerfeld R. 2013b. Gross anatomy of the female genital organs of the pampas deer (Ozotoceros bezoarticus, Linnaeus 1758). Anat Histol Embryol 42(3):168–174.

Rodrigues FHG, Monteiro-Filho ELA. 1999. Feeding behaviour of the pampas deer: A grazer or a browser? Deer Specialist Group News. 15:12.

Shao B, Long R, Ding Y, Wang J, Ding L, Wang H. 2010. Morphological adaptations of yak (Bos grunniens) tongue to the foraging environment of the Qinghai-Tibetan plateau. J Anim Sci 88:2594–2603.

Tadjalli M, Pazhoomand R. 2004. Tongue papillae in lambs: A scanning electron microscopic study. Small Rumin Res 54:157–164.

Qayyum MA, Fatani JA, Mohajir AM. 1988. Scanning electron microscopic study of the lingual papillae of the one humped camel, Camelus dromedarius. J Anat 160:21–26.

Villa AR, Beade MS, Barrios Lamuniére D. 2008. Home range and habitat selection of pampas deer. J Zool 276:95–102.

Zheng J, Kobayashi K. 2006. Comparative morphological study on the lingual papillae and their connective tissue cores (CTC) in Reeves' muntjac deer (Muntiacus reevesi). Ann Anat 188 (6):555–564.